



# Time for diagnosis ...

Remember how ...



**Liapis I.K.**  
Veterinarian  
Cert.Ophthalmology

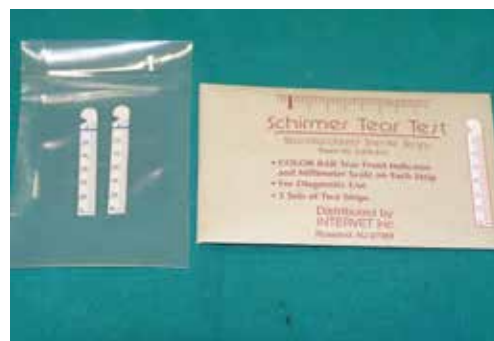## Schirmer tear and fluorescein tests

### ❖ Introduction

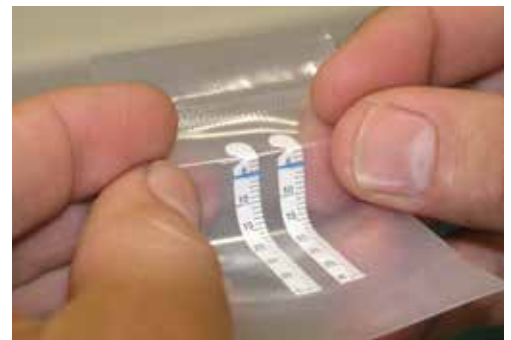The Schirmer tear test and the fluorescein test are two simple diagnostic procedures applied to establish a diagnosis of ocular diseases in domestic animals. Accurate performance of these tests minimizes misinterpretation of their results and leads to a safe diagnosis.

### ❖ Schirmer tear test

The Schirmer tear test (STT) estimates the aqueous phase of tears. Hence, it is used for diagnosing keratoconjunctivitis sicca (KCS) and quantitative KCS, in particular. Diagnosis of qualitative KCS is established using other tests. In clinical



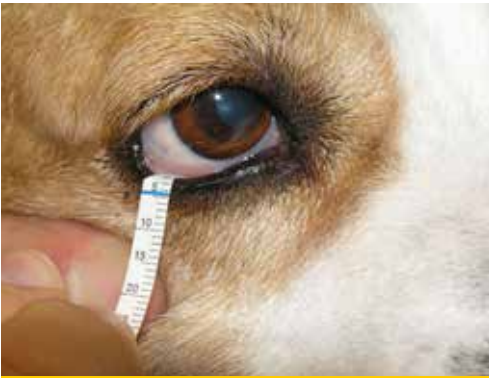**Figure 1.** The STT is performed using standard filter paper strips 5 X 35 mm with a notch 5 mm from its end, lined per millimeter, sterilized and packed in pairs. Some strips, such as the strip illustrated here, are impregnated with pigment in the notch for easier reading.



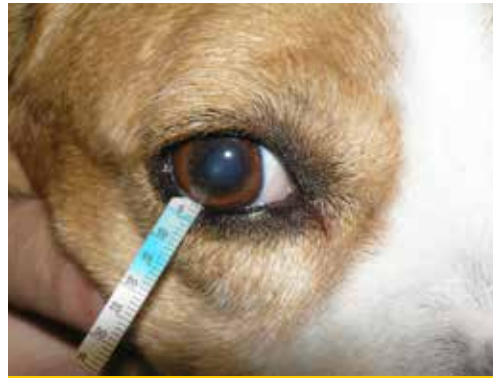**Figure 2.** Prior to opening the envelope, the strips are bent to the point of the notch in order to facilitate their apposition in the conjunctival sac.

**Corresponding author:**  
Placentia Veterinary Clinic  
Al. Panagouli 31 and Viotias  
15343, Ag. Paraskevi.  
liapis@plakentiavet.gr  
Tel. 2106082309





**Figure 3.** Initially, any mucus secretion is gently removed from the eyelids and conjunctival sac without excessive handling or liquid rinsing. The lower eyelid is then pulled down and the end of the strip that has been bent at the notch is placed in the lower conjunctival sac of the lateral half of the eyelid. The notch should be placed at the free edge of the eyelid.



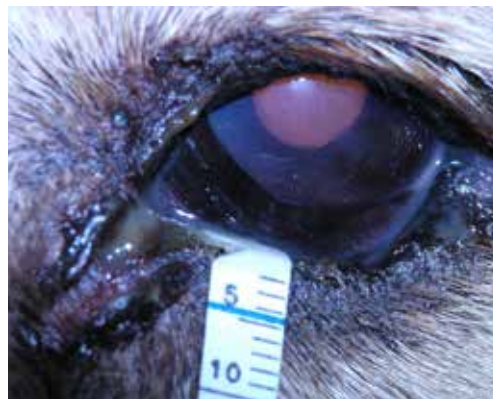**Figure 4.** The lower lid is allowed to come into position dragging the edge of the strip. In animals with difficulties in strip apposition, the eyelids may be held closed during the examination without affecting the test result. The strip is left for a minute and is then removed. Assessment should be made immediately since wetting of the strip can continue for a while.

practice, STT I is used commonly as it does not require local anesthesia. STT I measures both basic and reflex tear production. Normal values in the STT I range between  $18.64 \pm 4.47$  mm/min and  $23.90 \pm 5.12$  mm/min in the adult dog and  $14.3 \pm 4.7$  mm/min and  $16.92 \pm 5.73$  mm/min in the adult cat, although feline KCS is uncommon. In dogs, values lower than 5 mm indicate severe KCS. Values 5-10 mm indicate KCS while 10-15mm raises suspicion of the disease and should be eval-

uated in association with other clinical symptoms. The STT precedes the ophthalmic examination to avoid the induction of reflex tears due to handling, and before the topical use of other diagnostic solutions. Prior to re-examinations, topical application of ophthalmic solutions should be avoided. Before the test, any mucus discharge that may be present on the eyelids and conjunctival sac is gently removed without excessive handling or liquid rinsing.

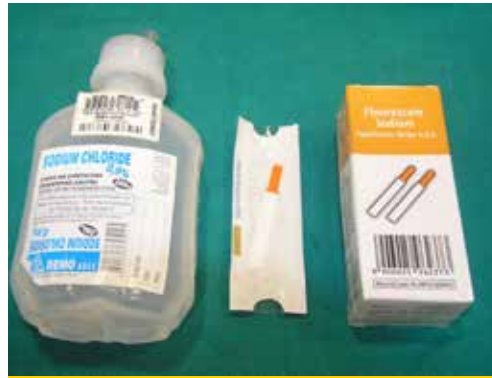

**Figure 5.** Evaluation of STT results in a 5-year old Shih-Tzu dog. Right eye, normal values: 21 mm. Left eye: 6 mm. Note also, on the left eye, the other symptoms of KCS (corneal oedema and mucopurulent discharge).



**Figure 6.** Findings of the STT in a 7-year old Griffon dog. Left eye values: 21 mm. Right eye values: 2mm. Please note other KCS symptoms present (corneal oedema, vascularization and mucopurulent discharge).





**Figure 7.** Fluorescein test using strips impregnated with dye and saline solution.

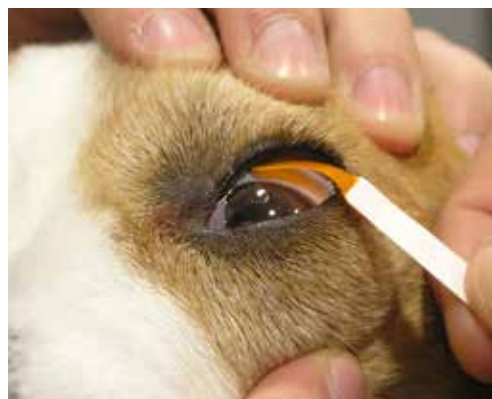

**Figure 8.** Initially, a drop of saline solution is placed at the end of the impregnated strip.

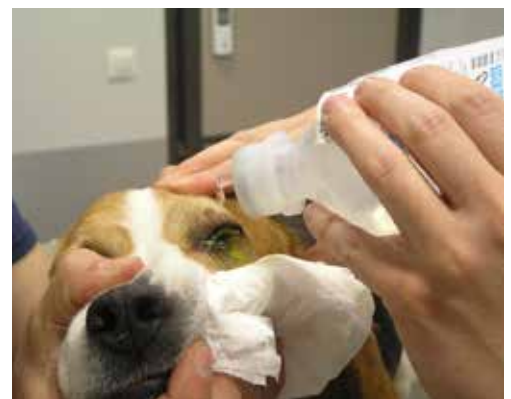### ❖ Fluorescein test

The most common indication for topical use of fluorescein, which will also be mentioned here, is the detection of corneal ulcers. Fluorescein is additionally used to detect aqueous humour leakage from the anterior chamber (Seidel test), for qualitative KCS diagnosis (break up time), and to examine lacrimal apparatus patency. Fluorescein has the maximum spectral absorption of light at 490 nm (blue light) and has the capacity to convert 100% of the absorbed light at

520 nm (green light). For this reason, its visualization is easier when illuminated with blue light. Fluorescein is highly lipophobic and hydrophilic and thus not normally absorbed by the corneal epithelium because of fat contained in the cell membranes. With the occurrence of epithelial damage, fluorescein is absorbed by the corneal stroma giving the characteristic green colour. Fluorescein is not absorbed by Descemet's membrane. Consequently, only the periphery of a pre-Descemet ulcer is stained rather than its bottom.

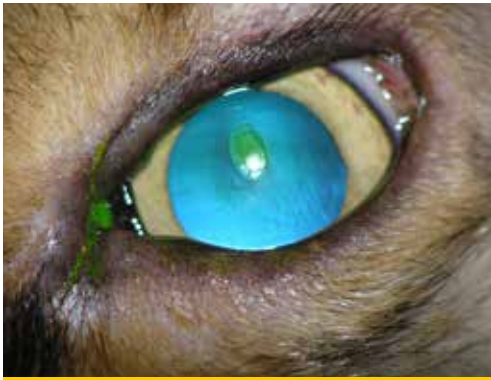

**Figure 9.** The upper eyelid is pulled up and the impregnated strip is attached to the bulbar conjunctiva. Avoid contact of the strip with the cornea, as it may cause epithelial abrasions and false-positive results.

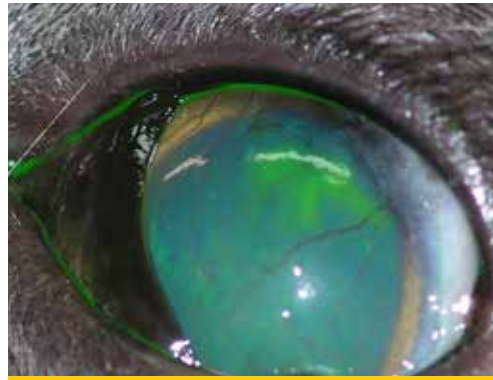


**Figure 10.** Rinse the corneal surface and conjunctival sac with normal saline in order to remove excessive dye. Fluorescein may be attached to mucus, hair and debris and could lead to false-positive results.





**Figure 11.** Fluorescein test in a 9-year-old mongrel dog. Fluorescein dyes the corneal stroma at the wound area and the surrounding detached epithelium, less intensely. Typical picture of an indolent corneal ulcer.

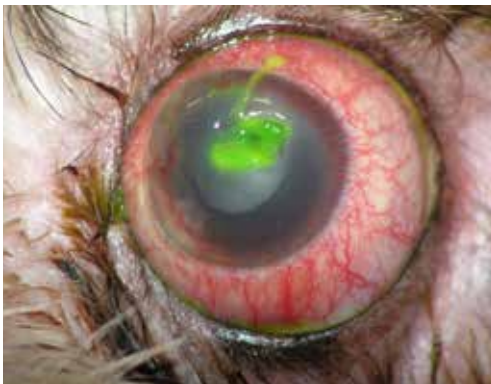

**Figure 12.** Fluorescein test in a four-year-old cat. Recurrent herpetic keratitis due to FHV-1 infection. Typical dendritic ulcer. Note also the corneal oedema and vascularization.

Fluorescein is available on the market either in single dose vials of 2% solution or in disposable sterile paper strips. The second form is easier to find in Greece. Multi-dose solutions should be avoided as they are considered to be contaminated. A fluorescein stain may be seen directly. For a safer evaluation of the test, a blue colour light in a dark environment can be used with the aid of magnification.

### ❖ Suggested Reading

1. Featherstone HJ, Heinrich CL. Ophthalmic examination and diagnostics Part 1. In : Veterinary Ophthalmology. Gelatt KN, Gilger BC, Kern TJ (ed). 5<sup>th</sup> edn. John Wiley & Sons, Inc: 2013, pp. 533-613.



**Figure 13.** Fluorescein test of a 6-year-old Lhasa Apso dog. Inadequate rinsing of the eye after fluorescein use, complicates the test assessment. An amount of stained mucus is not removed from the ulcer; hence, it is difficult to identify its exact depth and extent. In addition, a part of the mucus extends to the upper cornea, giving false-positive results.

